



PATIENT

Perla Santos

SPECIES

Canine

BREED

Mix

SEX

Female Spayed

AGE

10 years

WEIGHT

11.14lbs

INTERPRETED BY

Maggie Machen
Lamy, DVM
DACVIM (Cardiology)

PRESENTING CLINICAL SIGNS

History: Perla has a history of cutaneous, low grade MCT removals and was noted to have a heart murmur in August. Persistent coughing - rDVM started her on pimobendan, lasix and hycodan. Her coughing improved (has not been given hycodan x one week). Good appetite and normal activity level. On exam, NSR, grade III/VI murmur with PMI left apical area, PSS, lung fields clear. BP: 150mmHg x 5.

-Current medications: 1) Pimobendan/vetmedin 1.25mg 1 tab twice a day 2) Lasix/furosemide 20mg 1/2 tab twice a day 3) Hydrocodone with homatropine 5mg 1/4 tab as needed *No sedation for study.

ECHOCARDIOGRAM FINDINGS

2D, m-mode, color flow and Doppler imaging is available.

Left ventricle: The LV diameter is normal with adequate myocardial function. LV wall thicknesses are normal.

Left atrium: The left atrium is mildly dilated.

Mitral valve: The mitral valve is diffusely thickened with mild prolapse into the left atrial lumen. Mild to moderate eccentric mitral regurgitation with a normal velocity.

Aortic valve/aorta: The aortic valve is normal in morphology and mobility. Normal aortic outflow velocity; laminar flow. No aortic insufficiency.

Right ventricle: Normal right ventricular diameter and morphology indicating no overt evidence of pulmonary arterial hypertension.

Right atrium: Normal RA dimension.

Tricuspid valve: The tricuspid valve appears mildly thickened with mild septal prolapse and mild to moderate tricuspid regurgitation. Velocity consistent with early pulmonary hypertension.

Pulmonic valve/pulmonary artery: The pulmonic valve is normal in morphology and mobility. No pulmonic insufficiency. Normal RVOT velocity; laminar flow.

Pericardium/other: No pericardial or pleural effusion noted. No obvious cardiac masses.

Heart rhythm: ECG reveals a sinus rhythm with an average HR of 130bpm.

IMAGING

PERFORMED BY

Pamela Harrigan,
RDCS

HOSPITAL NAME

Mass Veterinary
Services

REFERRING VET

Dr. Masloski

INVOICE

22884

DATE

3/2/22

2-Dimensional Measurements

Ao diam (cm)	1.1
LA diam (cm)	1.7
LA:Ao (Swe)	1.55
IVS thickness (cm)	0.6
LVID diastole (cm)	2.3
PW thickness (cm)	0.6
LVID systole (cm)	0.9
FS (%)	60

Doppler Measurements

PV Vmax (m/s)	1.0
AoV Vmax (m/s)	1.4
MR Vmax (m/s)	6.0
TR Vmax (m/s)	2.9
TR PG (mmHg)	3.4

INTERPRETATION OF THE FINDINGS

The cause of the murmur is chronic degenerative valve disease causing mild to moderate mitral and tricuspid regurgitation. Lack of significant left atrial enlargement indicates the current risk for complication is low. Mild pulmonary hypertension is noted which should be monitored going forward. No additional issues are identified. Assessment of progression in the future will help predict long term prognosis, which is highly variable at this stage (B1).



PATIENT
Perla Santos

SPECIES
Canine

BREED
Mix

SEX
Female Spayed

AGE
10 years

WEIGHT
11.14lbs

INTERPRETED BY
Maggie Machen
Lamy, DVM
DACVIM (Cardiology)

IMAGING PERFORMED BY
Pamela Harrigan,
RDCS

HOSPITAL NAME
Mass Veterinary Services

REFERRING VET
Dr. Masloski

INVOICE
22884

DATE
3/2/22

Given these findings, it is reasonable to continue Pimobendan as prescribed. No obvious indication for Lasix therapy prior to congestive heart failure. The cough is suspected to be non-cardiac in origin and other possibilities should be considered. Primary airway disease is suspected given the chronicity of the symptom and more aggressive Hydrocodone is recommended.

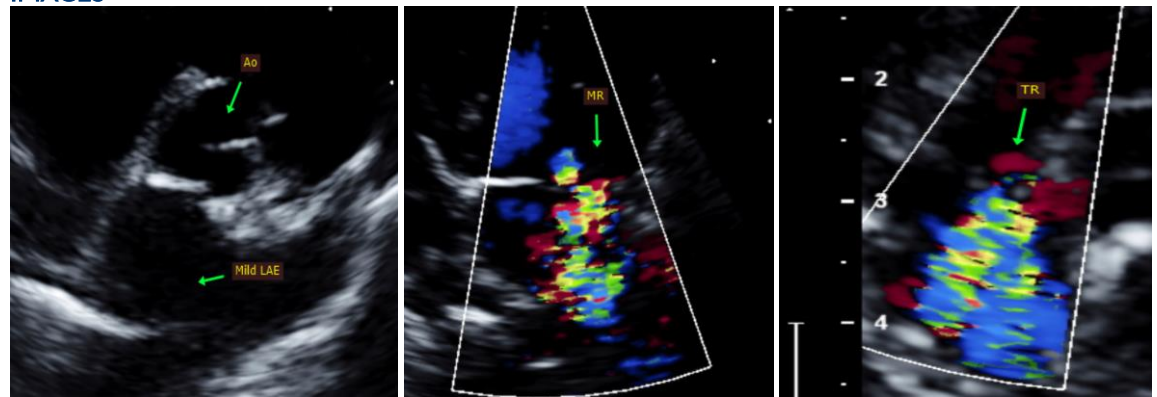
RECOMMENDATIONS

- Discontinue Lasix as discussed.
- Continue Pimobendan 0.3mg/kg PO q12h.
- Consider primary respiratory cause of coughing. CXR, course of Baytril, more aggressive Hydrocodone, etc. may be beneficial.
- Omega fatty acid supplementation and mild salt restriction may be of some long-term benefit.
- Anesthetic risk is considered mild if needed. Cardiac protective drug choices (opioid/benzodiazepine premedication, propofol or alfaxalone induction, isoflurane gas) are recommended. Pre-oxygenate for 5-10 minutes prior to induction. Monitor for arrhythmias, hypotension, and hypoxia both intra and post-operatively and intervene as necessary. Mild IV fluid restriction is recommended to avoid fluid overload. Avoid heart rate stimulating drugs such as atropine unless clinically indicated.
- Monitor for development of a cough, labored breathing, exercise intolerance or collapse episodes.

PLAN

- Recommend conservative monitoring with a recheck echocardiogram in 6 months, sooner if any development of clinical signs.

IMAGES





Mass Veterinary
Services



SonoPath
Clinical Sonography & Telectology
EDUCATIONAL TELECONSULTATION SERVICES™
1-800-838-4268 info@sonopath.com SonoPath.com

PATIENT

Perla Santos

The information and recommendations provided are based on the images presented by the referring veterinarian. No evaluation can be communicated regarding pathology that was not visible in the image/video clips provided.

SPECIES

Canine

Thank you for this referral. This report was generated using transcription software, and minor dictation errors may be present. If the clinical or image interpretation does not parallel your findings or if I can be of any further assistance, please contact me.

BREED

Mix

Maggie Machen Lamy, DVM
Diplomate of the American College of Veterinary Internal Medicine (Cardiology)
info@sonopath.com

SEX

Female Spayed

Echocardiogram performed by: Pamela Harrigan, RDCS
Pet Animal Ultrasound Service (4paus.com)

AGE

10 years

WEIGHT

11.14lbs

INTERPRETED BY

Maggie Machen
Lamy, DVM
DACVIM (Cardiology)

**IMAGING
PERFORMED BY**

Pamela Harrigan,
RDCS

HOSPITAL NAME

Mass Veterinary
Services

REFERRING VET

Dr. Masloski

INVOICE

22884

DATE

3/2/22